©2021 ASP Ins., *Afarand Scholarly Publishing Institute, Iran*
ISSN: 7687-2645. Journal of Clinical Care and Skills. 2021;2(4):207-211.

Efficacy of Aqueous Extract of *Allium sativum* and Tamsulosin Comparison on Reducing Pain and Expulsion of Kidney and Ureter Stones in Adult Patients

Journal of Clinical Care and Skills

ARTICLE INFO

Article Type
Original Research

Authors
Mehrabi S.[1] *MD,*
Shakeri N.*[1] *PhD,*
Mehrabi A.[1] *MD*

How to cite this article
Mehrabi S, Shakeri N, Mehrabi A. Efficacy of Aqueous Extract of *Allium sativum* and Tamsulosin Comparison on Reducing Pain and Expulsion of Kidney and Ureter Stones in Adult Patients. Journal of Clinical Care and Skills. 2021;2(4):207-211.

[1] Urology Department, Medicinal Plants Research Center, Yasuj University of Medical Sciences, Yasuj, Iran

Correspondence
Address: Urology Department, Medicinal Plants Research Center, Yasuj University of Medical Sciences, Yasuj, Iran
Phone: -
Fax: -
Nahid-t88@yahoo.com

Article History
Received: November 13, 2021
Accepted: December 20, 2021
ePublished: January 19, 2022

ABSTRACT

Aims Due to the widespread use of *Allium sativum* or garlic for food and medical purposes as well as the diuretic, analgesic, anti-inflammatory, and antispasmodic effects of garlic and its extract in various diseases, this study aimed to compare the effect of aqueous extract of *Allium sativum* and tamsulosin on reducing pain and expulsion of kidney and ureter stones in adult patients.

Materials & Methods In this clinical trial study, 80 patients older than 18 with kidney and ureteral stones less than 10mm were randomly assigned to one of the two groups, including tamsulosin as a control group and intervention group (*Allium sativum* or garlic). A tamsulosin capsule was administered one capsule every night for two weeks in the first group. In the second group, *Allium sativum* was prescribed in a dose of 900 mg per day in tree-divided capsules with a glass of water for two weeks. Two weeks later, patients were visited, KUB or sonography was performed, and the amount of stone change and the presence of residual stones were measured and recorded. The patient's pain level was checked using a visual analog scale, and data were collected during treatment and at the end of the study. All data were analyzed using SPSS software version 21.

Findings The mean age of patients in the control and intervention groups were 48.44±14.65 and 44.18±12.90 years, respectively (p=0.82). The size of stones after treatment in the intervention and control groups were 8.05±3.79 and 6.76±2.51mm, respectively (p=0.142). The mean pain intensity based on visual pain criteria before treatment was not significantly different in the two groups (p=0.438). Still, after treatment, the pain level in the intervention group compared to the control group significantly decreased (p=0.001).

Conclusion The results showed that the size and expulsion of stones treatment were not significantly different between the two groups. Still, the severity of pain in the *Allium sativum* group was significantly reduced compared to the control group. It can be used as an adjunct therapy to control pain and help the passage of stones.

Keywords Urinary Stones; Medical Therapy; Tamsulosin; *Allium sativum*

CITATION LINKS

[1] Urinary lithiasis: Etiology, diagnosis and medical management [2] Nephrolithiasis: A consequence of renal epithelial cell exposure to oxalate and calcium oxalate crystals [3] Phytotherapy and renal stones: the role of antioxidants [4] Extracorporeal shockwave lithotripsy versus laser lithotripsy by semirigid ureteroscope in treatment of upper ureteral stones [5] Tamsulosin for ureteral stones: A systematic review and meta-analysis of a randomized controlled trial [6] Antimicrobial activity of garlic (Allium sativum) on selected uropathogens from cases of urinary tract infection [7] The effect of immunomodulator fraction of garlic (R10) on blood pressure, protein, creatinine and uric acid in pregnant and non-pregnant mice [8] Preventive and therapeutic role of garlic (Allium sativum) on renal complications in rats with diabetes mellitus [9] Herbal medicines and perioperative care [10] Garlic reduces dementia and heart disease risk [11] Historical perspective on the use of garlic [12] Garlic prevents hypertension induced by chronic inhibition of nitric oxide synthesis [13] Pharmacological and therapeutic attributes of garlic (Allium sativum Linn.) with special reference to Unani medicine-A review [14] Diuretic, natriuretic and hypotensive effects produced by Allium sativum (garlic) in anaesthetized dogs [15] Ethanolic extract of garlic for attenuation of gentamicin-induced nephrotoxicity in wistar rats [16] Does tamsulosin change the management of proximally located ureteral stones? [17] Traditional uses, phytochemistry and pharmacological properties of garlic (Allium sativum) and its biological active compounds [18] Tamsulosin facilitates earlier clearance of stone fragments and reduces pain after shockwave lithotripsy for renal calculi: Results from an open-label randomized study [19] Possible interactions between garlic and conventional drugs: A review

Copyright© 2021, the Authors | Publishing Rights, ASPI. This open-access article is published under the terms of the Creative Commons Attribution-NonCommercial 4.0 International License which permits Share (copy and redistribute the material in any medium or format) and Adapt (remix, transform, and build upon the material) under the Attribution-NonCommercial terms.

Introduction

Urinary stones are the third most common urinary tract disease after infection and prostate diseases. Their prevalence is estimated between 1-15% in different societies and areas in the world [1, 2]. In addition to intractable pain, high recurrence, and high cost for health systems if they don't treat properly, 10-20% of cases cause unilateral or bilateral renal failure. In the last four decades, with the advent of lithotriptors, there has been a huge revolution in the treatment of stones. However, due to the high recurrence rate, unbearable pain when expelling stones, and various complications, the need for medical treatments to prevent, help expel stones and reduce pain is felt more frequently [1, 3]. One of the drugs used after lithotripsy to help excrete kidney and ureteral stones is oral tamsulosin, a specific inhibitor of alpha receptors that helps to expel stones and reduce symptoms by relaxing ureteral smooth muscle. Although it reduces pain, it has little effect on stone passage and can cause complications in some patients [2-5].

Garlic, scientifically known as *Allium sativum*, has been used as a medicine for thousands of years in various nations and civilizations, including its use in the Egyptian manuscript Ibres, written on a papyrus 1550 BC. Garlic is recommended to treat various ailments such as headache, wound healing, and heart spasms and as a diuretic [4-8]. In the Greek sage, Hippocrates used garlic to treat infections, toothaches, and chest pains. Garlic has been used for centuries as herbal medicine to treat abdominal pain. Several studies have anti-spasmodic, anti-inflammatory, and analgesic effects due to interaction with prostaglandin and cyclooxygenase pathways [9-12]. Although some herbal or chemical drugs are used for the treatment or passage of urinary stones, most have little efficacy, especially for stones larger than 6mm [3, 5, 13, 14].

Due to the widespread use of garlic for food and medical purposes as well as a diuretic, analgesic, anti-inflammatory, and antispasmodic effects of *Allium sativum* and its extract in various diseases, this study aimed to compare the effect of aqueous extract of *Allium sativum* and tamsulosin on reducing pain and expulsion of kidney and ureter stones in adult patients.

Materials and Methods

This study is a randomized controlled clinical trial conducted in 2018 on patients with kidney, and ureteral stones smaller than 10mm referred to the Urology Clinic of Shahid Mofateh in Yasuj, Iran. Considering the 5% alpha and 80% test power, 80 participants (40 patients in each group) were estimated as the sample size using the Cochrane model. First, a convenience sampling method was used for selecting participants. Then, using the random sampling method, they were assigned to intervention: *Allium sativum* (n=40) and control: tamsulosin (n=40) groups. Patients were included in the study who were older than 18 years, did not indicate immediate intervention and severe pain, and were seeking drug treatment. Patients with cardiovascular or pulmonary disease, Coagulation disorders, uncontrolled blood pressure, pregnant women, and those with a painkiller or narcotics or a history of drug allergies were excluded. Then, if there were no complications after obtaining written consent, patients were randomly assigned to intervention and control groups (Diagram 1).

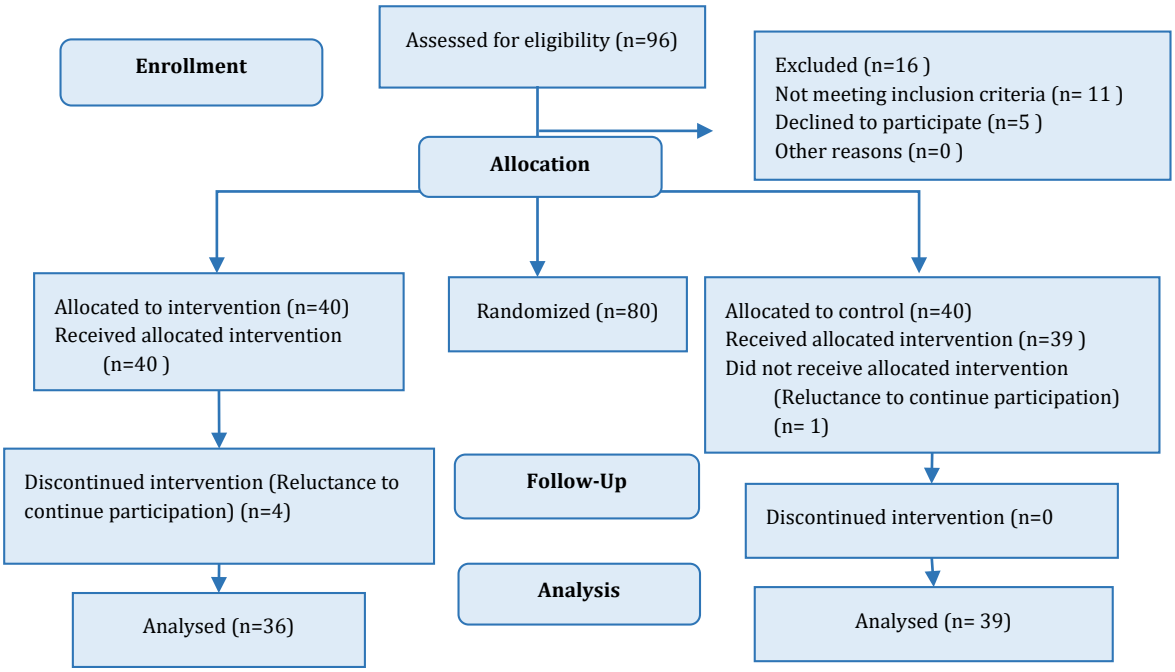

Diagram 1) CONSORT Flow Diagram

The patient's pain level was checked using a Visual Analog Scale (VAS) from 1-10 score. Patients were asked to record pain intensity between 1 and 10 based on VAS during pain. Also, characteristics such as age, sex, location of stones, and mean several stones were recorded in the checklist.

This study was approved by the ethics committee of Yasuj University of Medical Sciences, and the informed consent to participate in the study. All patients underwent a complete history and physical examination and baseline serum tests including PT, PTT, CBC, Hb, Na, K, kidney function tests (BUN, Cr), and complete urinalysis and urine culture. In the first group, after performing an ultrasound and ensuring the presence of stones smaller than 10mm, the tamsulosin capsule was administered one capsule every night for two weeks. In the second group (intervention), The *Allium sativum* was sliced and dried in shadow after determining the herbarium number. The ground *Allium sativum* was prepared as aqueous extract and prepared in the form of capsules and was prescribed with a dose of 900mg per day in the form of 3 capsules (2 capsules after lunch and one capsule after lunch dinner) with a glass of water for two weeks. In both groups, diclofenac sodium oral analgesia was used to relieve pain in terms of weight. If there was no response to analgesic or intervention indications, the necessary lithotripsy treatment was performed. It was also recommended that they exercise and walk for at least 30 minutes a day and consume 10-12 glasses of water daily. Two weeks later, patients were visited KUB, or ultrasonography was performed, and the change of stone size and the presence of residual stones were measured and recorded. Ultrasounds were performed in both groups by a radiologist. Data were collected during treatment and at the end of the study at 3rd week.

All data were analyzed using SPSS 21 software. Descriptive statistics, including frequency, mean, and standard deviation, analyzed the findings. Then chi-square and independent t-tests were used to compare the groups. A significance level of 0.05 was considered.

Findings

One patient in the control group (Receiving tamsulosin) and 4 in the intervention group (receiving *Allium sativum* extract) lost from follow-up. The mean age of patients in the control and intervention groups was 48.44±14.65 and 44.18±12.90 years, respectively. There was no significant difference between the two groups regarding age (p=0.82). Also, there were no significant differences between the two groups in patients' demographic characteristics, such as age, sex, location of stones, and mean several stones. Regarding the position of stones in the control group, 94.6% were in the kidney or kidney-ureter, 79.4% in the intervention group, and there was no significant difference between the two groups (p=0.13).

The size of stones before treatment had no significant difference between the two groups. Also, after the intervention, the mean stone size in the intervention and control groups was 8.05±3.79 and 6.76±2.51mm, respectively, with no statistically significant difference between the two groups (Table 1).

Table 1) Comparing of mean stone size (mm) between the two groups

Intervention	*Allium sativum*	Tamsulosin	p-value
	Mean±SD	Mean±SD	
Before	9.91±1.39	8.41±1.68	0.06
After	8.05±3.79	6.76±2.51	0.142

Before treatment, the mean pain intensity was not significantly different between the two groups (Table 2). Still, after treatment, the pain score in the intervention group compared to the control group decreased significantly (Table 3).

Table 2) Comparing pain intensity between groups before treatment

Pain intensity	*Allium sativum*	Tamsulosin	p-value
	N (%)	N (%)	
Mild	18 (47.06)	13 (33.3)	0.43
Moderate	13 (32.35)	16 (41.0)	
Severe	8 (20.58)	10 (25.6)	
Total	36(100%)	36(100%)	

Table 3) Comparing pain intensity between groups after treatment

Pain intensity	*Allium sativum*	Tamsulosin	p-value
	N (%)	N (%)	
Mild	24 (66.6)	11 (27.7)	0.001
Moderate	10 (27.7)	16 (41.7)	
Severe	2 (5.5)	12 (30.5)	
Total	36 (100)	39 (100)	

There was no significant difference between the two groups incomplete passage of stones or residual stones less than 4mm (Table 4).

Table 4) Comparing the efficacy of treatment after interventions between two groups

Efficacy	*Allium sativum*	Tamsulosin	p-value
	N (%)	N (%)	
Complete	16 (44.4)	9 (23.10)	0.46
Partial	10 (27.8)	15 (38.45)	
Failure	10 (27.8)	15 (38.45)	

Discussion

Currently, people use different methods to remove stones from the urinary tract, such as supportive methods (fluid intake, mobility, acidic and alkaline solvents) or surgical methods (removal of obstruction, extracorporeal lithotripsy, urethral lithotripsy, Bone crushing through the skin, and open surgery [1, 3, 5]. Oral tamsulosin is used to expel kidney and ureteral stones after crushing. It is a specific inhibitor of alpha receptors that helps to expel stones and reduce symptoms by relaxing ureteral smooth muscle [5, 13-16]. With the clarification of side effects and harmful effects of chemical drugs, the issue of

returning to herbal and natural drugs has been considered by researchers [3, 6, 11]. This study aimed to compare the effect of hydroalcoholic extract of garlic and tamsulosin on excretion of 4-10mm kidney and ureteral stones in patients referred to urology clinic in 2018.

The severity of pain in the intervention group (consumption of *Allium sativum* extract) compared to the control group (receiving tamsulosin) was significantly reduced, which may be due to antispasmodic and analgesic effects of *Allium sativum*. Also, in the study of Tesfaye *et al.,* the various effects of garlic, including its anti-stone and analgesic effects, have been mentioned [17], which is consistent with the effects of reducing pain in our study. Probably garlic decreases the severity of pain during stone passage due to its analgesic, anti-inflammatory, and antispasmodic effects.

In the study of Naja *et al.,* the effect of tamsulosin on the clearance of stones after ESWL was investigated. It was found that tamsulosin reduces the severity of pain and facilitates the clearance of stones after ESWL [18]. There was no significant difference in mean stone size between the two groups before and after treatment in this study. Although the stone size decreased after the intervention compared to before in the control group with Tamsulosin 1.21mm and the intervention group 1.50, this difference between the two groups was not significant. Also, in another study conducted by Iu *et al.,* the effect of tamsulosin on ureteral stones was investigated. It was observed that tamsulosin consumption increases the rate of stone excretion compared to the control group and reduces the need for drugs and excretion time [5]. In this study, the effect of tamsulosin and *Allium sativum* extract on the expulsion of stones was not significant and is inconsistent with the results of the above studies, but as we see in the results taking tamsulosin for two weeks clinically reduced the number of stones in the control group but had no significant effect on the expulsion of stones. It probably is due to two factors: at first, tamsulosin facilitates the clearance of stones in the ureter; in the present study, many stones were in the kidney or both kidney and ureter that decreased the effect of both extract and tamsulosin. And the second reason is the short time of study that decreases the effect of drugs and needs more time for better effect.

In the study of Pantoja and Nasir *et al.* and other studies, various properties of *Allium sativum*, including a diuretic, natriuretic, antioxidant, and vasodilator properties of it, have been mentioned [13-18]. Although the above studies have been performed in rats, they are consistent with our study's diuretic, stone-passage, and ureteral dilation. In the study of Kansara *et al.,* the various effects of garlic, including its role in the treatment of urinary tract stones diuretic and antibacterial effects, were mentioned [19]. Although there was no significant difference between the efficacy of tamsulosin and garlic in the effect of stone excretion and residual stones, the highest stone excretion (less than 4mm) occurred in the group with garlic intervention (44%). With tamsulosin, only 23.1% of the stones became excreted in the group. This effect can be due to the diuretic and dilating properties of garlic.

This study also had some limitations. Some patients refused to use the unpleasant smell of raw garlic and its gastrointestinal side effects, but this problem was solved after extracting and turning it into capsules. Another limitation was the short time of study that probably decreased the effect of both extract and tamsulosin, and the results may change with increasing study duration.

It is recommended to conduct studies with larger sample sizes, different doses, and different forms of *Allium sativum* and longer, especially in larger stones.

Conclusion

The size of stones after treatment is not different in the two groups. Still, the severity of pain in the intervention group (consumption of *Allium sativum* extract) was significantly reduced compared to the control group (receiving tamsulosin only). It can be used as a complementary herbal therapy to control pain in urinary stones.

Acknowledgments: We present our appreciation to the respected Vice President Technical and Research Department of Yasuj University of Medical Sciences that provides the facility to perform this project by their material and ethical support. Additionally, we thank all staff of the Medicinal Plants' Research Center of Yasuj University of Medical Sciences who assisted us in performing this project.

Ethical Permissions: This study was approved by the ethics committee of Yasuj University of Medical Sciences (IR.YUMS.REC.1397.101) and registered in the Iranian Registry of the clinical trial with the IRCT number IRCT20081011001323N20.

Conflicts of Interests: This manuscript was extracted from a project with code number 960358.

Authors' Contribution: Mehrabi S (First Author), Main Researcher/Methodologist/Discussion Writer (40%); Shakeri N (Second Author), Assistant Researcher/Introduction Writer (30%); Mehrabi A (Third Author) Assistant Researcher/Statistical Analysis (30%)

Funding/Support: The study was supported financially by the Deputy of Research of Yasuj University of Medical Sciences.

References

1- Menon M, Resnick M. Urinary lithiasis: Etiology, diagnosis and medical management. In: Wein AJ, Kavoussi LR, Novick AC, Partin AW, Peters CA, editors. Campbell's Urology. 8th edition. Philadelphia: Saunders; 2007. p: 3229-305.

2- Khan SR, Thamilselvan S. Nephrolithiasis: A consequence of renal epithelial cell exposure to oxalate and calcium oxalate crystals. Mol Urol. 2000;4(4):305-12.

3- Grases F, Prieto RM, Gomila I, Sanchis P, Costa-Bauzá A. Phytotherapy and renal stones: the role of antioxidants. A pilot study in Wistar rats. Urol Res. 2009;37(1):35-40.

4- Mehrabi S, Rahmani A, Mehrabi A, Motlagh A. Extracorporeal shockwave lithotripsy versus laser lithotripsy by semirigid ureteroscope in treatment of upper ureteral stones. Acta Med Mediter. 2016;1(32):2075.
5- Lu Z, Dong Z, Ding H, Wang H, Ma B, Wang, Z. Tamsulosin for ureteral stones: A systematic review and meta-analysis of a randomized controlled trial. Urol Int. 2012;89(1):107-15.
6- Lionel OO, Adegboyega IP, Ezekiel AO, Olufunke BC. Antimicrobial activity of garlic (Allium sativum) on selected uropathogens from cases of urinary tract infection. Annals Trop Pathol. 2020;11(2):133-8.
7- Moaied Mohseni S, Mirsharif ES, Aiiobi F, Eghtedardoost M, Emadi SMR, Heshmati M, et al. The effect of immunomodulator fraction of garlic (R10) on blood pressure, protein, creatinine and uric acid in pregnant and non-pregnant mice. Daneshvar Med: Basic Clin Res J. 2020;19(4):17-26. [Persian]
8- Rashki KM, Gol A, Dabiri Sh, Javadi AR. Preventive and therapeutic role of garlic (Allium sativum) on renal complications in rats with diabetes mellitus. Iran J Biol. 2011;24(5):694-706. [Persian]
9- Ang-Lee MK, Moss J, Yuan C-S. Herbal medicines and perioperative care. JAMA. 2001;286(2):208-16.
10- Borek C. Garlic reduces dementia and heart disease risk. J Nutr. 2006;136(3):810S-2S.
11- Rivlin RS. Historical perspective on the use of garlic. J Nutr. 2001;131(3):951S-4S.
12- Pedraza-Chaverrí J, Tapia E, Medina-Campos ON, Angeles Granados MDL, Franco M. Garlic prevents hypertension induced by chronic inhibition of nitric oxide synthesis. Life Sci. 1998;62(6):71-7.
13- Nasir A, Fatma G, Neshat N, Ahmad M. Pharmacological and therapeutic attributes of garlic (Allium sativum Linn.) with special reference to Unani medicine-A review. J Med Plants Stud. 2020;8(3):6-9.
14- Pantoja CV, Chiang LC, Norris BC, Concha JB. Diuretic, natriuretic and hypotensive effects produced by Allium sativum (garlic) in anaesthetized dogs. J Ethnopharmacol. 1991;31(3):325-31.
15- Nasri H, Nematbakhsh M, Rafieian-Kopaei M. Ethanolic extract of garlic for attenuation of gentamicin-induced nephrotoxicity in wistar rats. Iran J Kidney Dis. 2013;7(5):376-82.
16- Yencilek F, Erturhan S, Canguven O, Koyuncu H, Erol B, Sarica K. Does tamsulosin change the management of proximally located ureteral stones? Urol Res. 2010;38(3):195-9.
17- Tesfaye A, Mengesha W. Traditional uses, phytochemistry and pharmacological properties of garlic (Allium sativum) and its biological active compounds. Int J Sci Res Eng Technol. 2015;1:142-8.
18- Naja V, Agarwal MM, Mandal AK, Singh SK, Mavuduru R, Kumar S, et al. Tamsulosin facilitates earlier clearance of stone fragments and reduces pain after shockwave lithotripsy for renal calculi: Results from an open-label randomized study. Urology. 2008;72(5):1006-11.
19- Kansara MB, Jani AJ. Possible interactions between garlic and conventional drugs: A review. Pharm Biol Eval. 2017;4(2):73-81.