ASPI | Afarand Scholarly Publishing Institute; Turkey
ISSN: 7687-2645. Journal of Clinical Care and Skills. 2024;5(1):49-54 10.58209/jccs.5.1.49

Genital Tuberculosis in Women; A Systematic Review

ARTICLE INFO

Article Type
Systematic Review

Authors
NematiShahri F.[1] *MSc*
Pouresmaeil O.[1] *MSc*
Sharifi A.[1] *MSc*
Mardani F.[2] *BSc*
Mardaneh J.[3]* *PhD*

How to cite this article
NematiShahri F, Pouresmaeil O, Sharifi A, Mardani F, Mardaneh J. Genital Tuberculosis in Women; A Systematic Review. Journal of Clinical Care and Skills. 2024;5(1):49-54.

[1]Infectious Diseases Research Center, Gonabad University of Medical Sciences, Gonabad, Irann
[2]Microbiology Laboratory, Allameh Bohlool Hospital, Gonabad University of Medical Sciences, Gonabad, Iran
[3]"Department of Microbiology, School of Medicine" and "Infectious Diseases Research Centre", Gonabad University of Medical Sciences, Gonabad, Iran

***Correspondence**
Address: Faculty of Medicine, Gonabad University of Medical Sciences, Near Asian Road, Gonabad University of Medical Sciences Campus, Gonabad, Iran. Postal Code: 9691833181
Phone: +98 (51) 57225080
Fax: +98 (51) 5722302
Jalalmardaneh@yahoo.com

Article History
Received: December 18, 2023
Accepted: March 6, 2024
ePublished: March 12, 2024

ABSTRACT

Aims Female genital tuberculosis is an infrequent form of tuberculosis that is often underestimated due to its low prevalence in developed countries, difficult and delayed diagnosis, and misleading clinical presentation. This systematic review aimed to describe the epidemiology, clinical presentation, diagnosis, and treatment of female genital tuberculosis during 2000-2021.

Information & Methods The current study is a systematic review that was conducted through exploration of English keywords like "female genital tuberculosis", "vulva tuberculosis", "tuberculosis", and "genital system" as well as, Persian keywords. Furthermore, a similar search methodology was employed in various international databases, including PubMed, Scopus, and Web of Sciences, as well as in certain Iranian databases, like Irandoc and Magiran, between 2000 and 2021.

Findings Most patients (37.5%) were from India. Upper genital tuberculosis was more common among women of reproductive age, and the most involved upper genital organs were the endometrium and fallopian tubes. In contrast, vulvar tuberculosis was more prevalent in postmenopausal women, and the vulva was the most common site involved in lower genital tuberculosis. Weight loss (31.25%) and vaginal discharge (31.25%) were the most common symptoms reported by the study participants. The main histologic finding in female genital TB was the presence of epithelioid cell granulomas (81.25%). 29 (90.6%) patients received the standard antibiotic therapy (combination of rifampicin, isoniazid, ethambutol, and pyrazinamide), all of whom responded positively.

Conclusion Most patients experience prolonged vulva ulcers and inadvertently receive various antibiotics. The typical lesions are epithelioid cell granulomas, which may be accompanied by Langerhans giant cells.

Keywords Tuberculosis; Female Fertility; Genital Infection

CITATION LINKS

[1] Urogenital tuberculosis-epidemiology, pathogenesis ... [2] The coexistence of carcinoma and tuberculosis in the uterine ... [3] Diagnosis and treatment of ... [4] Female genital ... [5] Overview of tuberculosis of the female ... [6] Vaginal tuberculosis as differential diagnosis of cancer: A case ... [7] Postmenopausal tuberculosis ... [8] Vulval ... [9] Tuberculosis of the vulva masquerading as a sexually ... [10] Genital tuberculosis can present as disseminated ovarian carcinoma ... [11] Tuberculosis of the cervix: Case presentation and a review of ... [12] A rare case of vulvar ... [13] A rare case report of tuberculosis of the cervix and vulva in Zeinab... [14] Genital tuberculosis in postmenopausal ... [15] Tuberculosis of ... [16] A rare case of cervical tuberculosis simulating ... [17] Cervical tuberculosis detection in Papanicolaou-stained smear: Case ... [18] Genital tuberculosis as the cause of tuboovarian abscess ... [19] Tuberculosis at vulva and ... [20] Vulvar tuberculosis in a virgin girl: A rare ... [21] Vulvar ... [22] A case report; Tuberculosis of the ... [23] Periorificial cutaneous tuberculosis of ... [24] Primary tuberculosis vulva-A case ... [25] Primary vulval tuberculosis presenting as multiple vulval ulcers: A rare ... [26] Woody vulva: An unusual presentation of ... [27] A rare case of vulval ... [28] Cutaneous lymphangiectasia of the vulva secondary to pulmonary ... [29] Vulvar tuberculosis cutis orificialis concomitant to pulmonary ... [30] Tuberculosis and HIV co-infection; The deadly duos ... [31] Genital tuberculosis in postmenopausal women with variable clinical presentations: A report ... [32] Genital tuberculosis in a post-menopausal Caucasian woman: A ... [33] Vulvar tuberculosis-A rare manifestation of ... [34] Case report of pelvic tuberculosis resulting in Asherman's syndrome ... [35] Vulvar ... [36] A woman with disseminated tuberculosis experienced preterm delivery, fallopian tube pregnancy, and delivered ...

Copyright© 2024, the Authors | Publishing Rights, ASPI. This open-access article is published under the terms of the Creative Commons Attribution-NonCommercial 4.0 International License which permits Share (copy and redistribute the material in any medium or format) and Adapt (remix, transform, and build upon the material) under the Attribution-NonCommercial terms.

Introduction

Tuberculosis (TB), caused by bacteria belonging to the *Mycobacterium tuberculosis* complex, is one of the most common causes of death from infectious diseases worldwide [1]. The WHO reports that in 2019, an estimated 10 million people fell ill with tuberculosis (TB) worldwide. Tuberculosis after the Second World War was nearly eradicated in developed countries due to the spread of vaccination, early diagnosis, appropriate treatment, and improvements in life standards. However, in recent years, it has risen again due to increased migration and immunodeficiency diseases such as HIV, and it remains a major health problem in underdeveloped countries [2]. The disease is usually classified as pulmonary or extrapulmonary. Pulmonary tuberculosis (PTB) constitutes the more common clinical presentation of TB, and extrapulmonary involvement includes about a third of the cases [1]. The most common sites involved in extrapulmonary tuberculosis are the lymph nodes, pleura, bones, meninges, and urogenital tract. Genitourinary tuberculosis accounts for 15% of all extrapulmonary cases and can include various organs such as the ovaries, fallopian tubes, uterus, cervix, and vulva [3]. Female genital tuberculosis (FGTB) is generally caused by the reactivation of organisms from the systemic dissemination of *Mycobacterium tuberculosis* during the initial infection. The distribution occurs usually through hematogenous or lymphatic routes. Genital tuberculosis is rare, and its true prevalence is not specified because many cases remain unknown. Genital tuberculosis is mostly asymptomatic; However, genital tuberculosis can be clinically associated with different signs and symptoms such as infertility, amenorrhea, ascites, abdominal pain, and postmenopausal bleeding. Patients with FGTB receive similar medical therapy as patients with pulmonary TB, and excellent FGTB treatment rates have been reported. In the review of the literature, no comprehensive study was found addressing the systematic review of genital tuberculosis in females. This systematic review aimed to describe the epidemiology, clinical presentation, diagnosis, and treatment of FGTB during 2000-2021 and provide a new perspective on FGTB worldwide.

Information and Methods

This systematic review was conducted on the global literature on tuberculosis in the female reproductive system and vulva between 2000 and 2021. Various databases, including PubMed, Scopus, Embase, Web of Science, and Google Scholar, were utilized to gather the relevant studies. The retrieval process focused on English keywords like “female genital tuberculosis”, “vulva tuberculosis”, “tuberculosis”, “genital system” as well as Persian keywords. A similar approach was taken to identify related Persian articles in Iranian databases specific to Iran, such as Irandoc and Magiran. All types of studies (original, case reports, etc.) related to the theme of the present research were examined, but case report studies were the primary source of suitable articles.

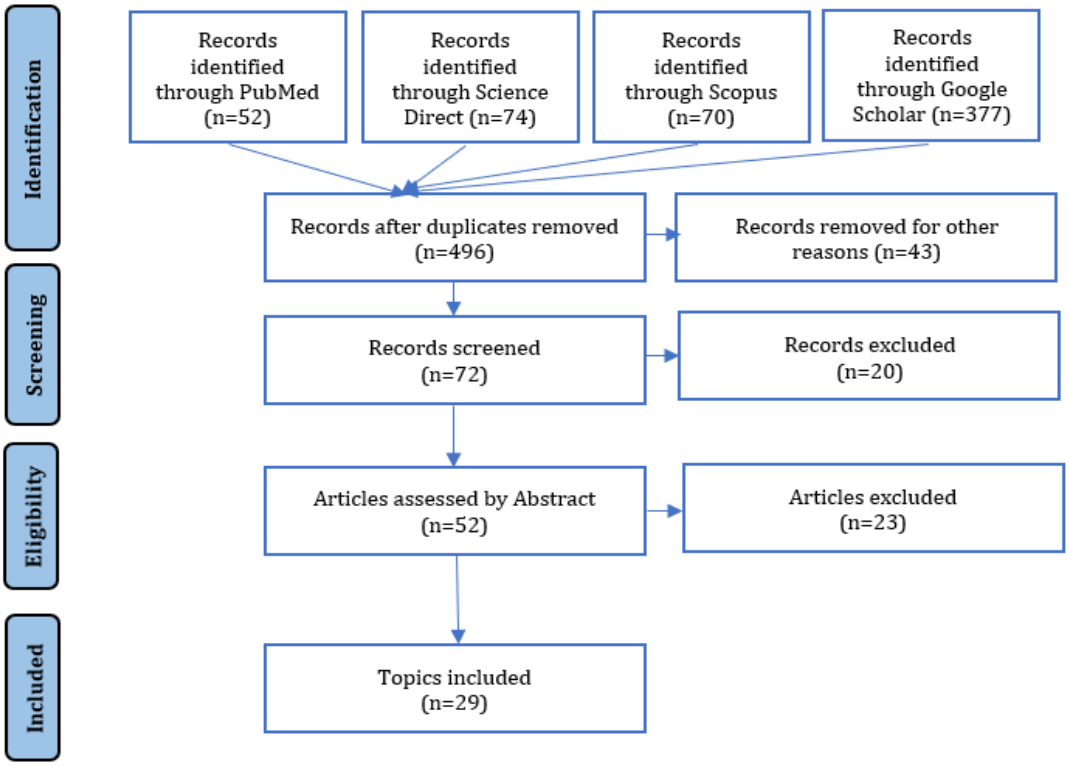

Figure 1. Included and excluded data flowchart

This review includes case report studies featuring female patients diagnosed with vulva or genital tuberculosis. Both English and Persian articles were considered for potential inclusion. The exclusion criteria were the unavailability of full-text articles, systematic reviews, narrative-only conference abstracts, multiple reports of the same data, and non-scientific diagnostic methods. 568 references in Persian and English were obtained from various research databases. After the elimination of duplicate entries, 72 references were retained and underwent abstract analysis conducted independently by two reviewers. Out of these, 52 references were considered to meet eligibility criteria. 23 references were excluded after the full-text review, and 29 studies satisfied the eligibility criteria and were consequently included in the analysis (Figure 1).

The critical appraisal checklist provided by the Joanna Briggs Institute (JBI) was employed to evaluate the overall quality of studies. This checklist has 8 parts and addresses various sections of the reports. Two reviewers independently assessed the validity of the studies.

Findings

During the twenty-one-year observational period (2000-2021), data about 32 patients with FGTB from 14 countries and regions was collected (Table 1).

The distribution of ages among the cases ranged from 14 to 83 years, with a median age of 52.5 years. 59.4% of the study population were postmenopausal women, while 40.6% of patients were their reproductive age. Five women (15.6%) had a history of pulmonary TB, and five other women had a familial history of TB. The geographical distribution of the FGT patients indicated that most were from India (12, 37.5%). It is revealed that the incidence of genital tuberculosis is high in countries with low socio-economic levels and poor people. The distribution of genital tuberculosis according to the involved organs was as follows: 16 cases (50%) of the vulva, 5 cases (15.6%) of the endometrium, 3 cases (9.3%) of the cervix, and 3 cases (9.3%) fallopian tubes. There were also multiple organ involvements in 5 cases (15.6%). Amongst four positive cases (12.5%) with infertility, three cases suffered from primary infertility, while one case had secondary infertility. Fertility data were not available in three single patients. Among the patients with infertility complaints, one case had endometrial TB, one case was diagnosed as cervical TB, and two cases had disseminated tuberculosis. The clinical features of genital tuberculosis are generally non-specific. Weight loss (31.25%) and vaginal discharge (31.25%) were the most common symptoms reported by the study participants. Other symptoms, such as amenorrhea, ascites, abdominal pain, postmenopausal bleeding, and fever, were less prevalent among patients. In all the patients with vulvar tuberculosis, the most common clinical complaint was the appearance of an ulcer on the outer area of the vulva. These ulcers had different clinical features, such as itch and pain. The main histologic finding in female genital TB was the presence of epithelioid cell granulomas that were observed in 81.25% of patients. Langhans-type multinucleated giant cells were present in 46.87% of the cases. Acid-fast bacilli (AFB) in tissue sections were detected in 46.87% of cases after Ziehl-Neelsen (ZN) staining. Seven patients (21.87%) had positive PCR results. 29 (90.6%) patients received the standard antibiotic therapy (combination of rifampicin, isoniazid, ethambutol, and pyrazinamide), resulting in a favorable treatment response for all individuals. Information regarding the treatment and outcomes of two patients remained undisclosed. Notably, treatment resistance was documented in only one case. An alternative regimen, including Zidovudine, Lamivudine, and Efavirenz, was used for a particular female patient who unfortunately succumbed to the illness. It is crucial to highlight that the patient was confirmed to be HIV positive.

Table 1. Data extracted from articles

Author	Year	Setting	Age	Prior history of TB	Familial history of TB	History of infertile	Symptoms	Genital site	Final detection method	Histopathological findings	Treatment	Out come
Sardana [9]	2001	India	28	No	No	No	Amenorrheic, ulcer on the left vulva	Vulva	AFB	Granuloma, Langerhan's giant cells, necrosis	Anti-tuberculosis quadruple	Treated
Manidakis [10]	2001	Greece	41	No	No	Yes primary	Abdominal pain, ascites, significant weight loss	Ovaries, uterine tubes, omentum	Histology, cultures of ascetic fluid	Granuloma	No	No
Lamba [11]	2002	Kenyan	29	No	Yes	No	Amenorrhea, weight loss	Endometria	Histopathology biopsy	Granuloma, giant cells	Anti-tuberculosis quadruple	Treated
LAM [12]	2007	Chinese	49	No	No	No	Painless vulvar ulcer, marked weight loss	Vulva	AFB, culture	Granuloma, Langhans' giant cells	Anti-tuberculosis quadruple	Treated
Akhlaghi [13]	2004	Iran	63/Postmenopausal	No	No	No	Dysuria, frequent urination, ulcer on the vulva	Cervix, vulva	Histopathology	No	Anti-tuberculosis quadruple	Treated
Krynytska [14]	2007	UK	63/Postmenopausal	No	Yes	No	Clinically abnormal appearance of the cervix with yellowish discharge	Cervix	AFB, culture	Granulomas, few giant cells	Anti-tuberculosis quadruple	Treated

Continue of Table 1 from the last page.

		UK	73/Postmenopausal	No	No	No	Brown vaginal discharge	Endometria	AFB	Granulomatous endometrium, well-formed granulomas, foreign body type giant cells,	Anti-tuberculosis quadruple	No
Paprikar [15]	2008	India	50/Postmenopausal	No	No	No	White colored discharge with foul smelling	Cervix and endometria	AFB	Granuloma, Langhans' giant cells, lymphocytic infiltrations	Anti-tuberculosis quadruple	No
Agrawal [16]	2009	India	26	No	No	No	Pain abdomen, irregular bleeding, discharge, significant weight loss	Cervix	AFB	Granulomatous inflammation, necrosis	Anti-tuberculosis quadruple	Treated
Gupta [17]	2009	India	24	No	No	Yes primary	Amenorrhea and primary infertility	Cervix	Histopathology biopsy	Granuloma, Langhans' giant cells	Anti-tuberculosis quadruple	Treated
Ilmer [18]	2009	Africa	35	No	No	No	Lower left-sided abdominal pain, elevated inflammation parameters	Left fallopian tube	PCR	Langhans' giant cells, Granulomatous	Anti-tuberculosis quadruple	Treated
Buppasiri [19]	2010	Thailand	60/Postmenopausal	No	No	No	Low grade fever, painful ulcer	Vulva	AFB	No	Anti-tuberculosis quadruple	Treated
Keshavarzi [20]	2011	Iran	14	No	No	No	Painful and itching ulcer	Vulva	AFB	Caseating Granulomatous Inflammation, Langhans' giant cells	Anti-tuberculosis quadruple	Treated
Shen [21]	2011	Taiwan	74/Postmenopausal	No	No	No	Vulvar itching, ulcerative lesion	Vulva	AFB, culture	Necrotizing granulomata	Anti-tuberculosis quadruple	Treated
Kitisupornpun [22]	2011	Thailand	27	Yes	No	No	Chronic painful ulcer, mucopurulent discharge, dysuria	Vulva	AFB	Granulomatous, Langhans type giant cells	Anti-tuberculosis quadruple	Treated
Jiménez-Gallo [23]	2012	Spain	78/Postmenopausal	No	No	No	Mild vulvar bleeding, a long-standing painful ulcer on the vulva	Vulva	PCR	Necrotic center of caseous appearance, epithelioid cells, Langhans-type multinucleated giant cells	Anti-tuberculosis quadruple	Treated
Agrawal [24]	2013	India	32	No	No	No	Mild weight loss, two non-healing ulcers	Vulva	AFB	Granulomatous, Langhans type giant cells	Anti-tuberculosis quadruple	Treated
Ener [25]	2013	India	46/Postmenopausal	No	No	No	Multiple small, painful, and itchy ulcers	Vulva	AFB	Granulomatous, Langhans type giant cells	Anti-tuberculosis quadruple	Treated
Bhupesh [26]	2014	India	55/Postmenopausal	No	No	No	Thickening and dark pigmentation of the vulvar skin, diffuse swelling of the vulva	Vulva	Histopathology biopsy	Granuloma, giant cells	Anti-tuberculosis quadruple	Treated
Iftikhar [27]	2015	Pakistan	50	No	No	No	Vaginal yellowish white discharge,	Vulva	Histopathology biopsy	Chronic caseating granulomatous inflammation	Anti-tuberculosis quadruple	Treated
Arya [28]	2015	India	75/Postmenopausal	Yes	No	No	Multiple raised lesions over the vulva, watery discharge per vagina	Vulva	Histopathology biopsy	Hyperkeratosis, acanthotic epidermis, lymphatics	Anti-tuberculosis quadruple	Treated
Oliveira [29]	2018	Brazil	59/Postmenopausal	No	Yes	No	Fever, dyspnea on medium efforts, weight loss, a shallow, large, friable, irregular ulcer	Vulva	PCR	Granulomas, caseous necrosis	Anti-tuberculosis quadruple	Treated
Paudel [30]	2018	Nepal	46/Postmenopausal	Yes	No	No	Multiple painful and itchy ulcerative discharging, fever, ulcerative vulvar lesion	Vulva	AFB	Caseating epithelioid cell granulomas	resistance to Anti-tuberculosis quadruple, Zidovudine, Lamivudine, Efavirenz	Died
Arora [31]	2018	India	59/Postmenopausal	No	No	No	Ascites, weight loss	Endometria	PCR	Granuloma, Langhans type giant cells	Anti-tuberculosis quadruple	Treated
		India	58/Postmenopausal	No	No	No	Postmenopausal bleeding	Both fallopian tubes	Histopathology biopsy	Chronic granulomatousume lymphadenitis	Anti-tuberculosis quadruple	Treated
		India	56/Postmenopausal	No	No	No	Weight loss	Left fallopian tubes	Histopathology biopsy	No	Anti-tuberculosis quadruple	Treated
Chishti [32]	2019	Caucasian	77/Postmenopausal	No	No	No	Substantial weight loss, yellowish offensive vaginal discharge	Endometria	AFB	Epithelioid granuloma	Anti-tuberculosis quadruple	Treated

Continue of Table 1 from the last page.

Bragança [33]	2019	Caucasian	83/Postmenopausal	yes	No	No	Vulvar edema and a strong smelling greenish vaginal discharge	Vulva	PCR, blood culture	Granulomatous Inflammation, Langhans' giant cells	Anti-tuberculosis quadruple	Treated
Louise Fowler [34]	2019	Ethiopia	34	No	Yes	Yes primary	Prolonged secondary amenorrhea, infertility	Endometria	AFB, culture	Necrotizing granulomas	Anti-tuberculosis quadruple	Treated
Singh [35]	2020	India	75/Postmenopausal	No	No	No	Itchy ulcerative lesion on the vulva	Vulva	Histopathology biopsy	Granuloma, Langerhans giant cells	Anti-tuberculosis quadruple	Treated
Carton [6]	2021	France	55/Postmenopausal	No	No	No	Pelvic pain, vulvar itching or burning, vaginal discharges, urinary frequency, weight loss, asthenia, cough and serous sputum	Anterior surface of vagina and cervix	Culture, PCR	Necrotizing gigntocellular epithelioid granuloma	Anti-tuberculosis quadruple	Treated
Cheng [36]	2021	China	31	Yes	Yes	Yes secondary	Nausea, vomit and severe headache	Disseminated tuberculosis pelvis, fallopian tube, endometria	Histopathology biopsy	No	Anti-tuberculosis quadruple	Treated

Discussion

The present study was conducted to perform a systematic review of studies that aims to describe the epidemiology, clinical presentation, diagnosis, and treatment of FGTB between 2000-2021 and to provide a fresh perspective on FGTB. The prevalence of female genital tuberculosis is often underestimated due to its low occurrence in developed countries, challenging and delayed diagnosis, and various nonspecific signs and symptoms. Consequently, the incidence of this illness in the communities cannot be accurately determined [4]. Female genital tuberculosis is more prevalent in underdeveloped and developing countries, particularly in India. It is indicated that the occurrence of TB is higher in economically disadvantaged countries with low socio-economic status, poverty, and residence. These factors can be considered as epidemiological factors related with the diagnosis of female genital tuberculosis. However, the examination of a small number of patients from developed countries indicates that genital TB in these countries has not been entirely eliminated and should be considered. Female genital TB can affect females of all age groups. The age range of the cases spanned from 14 to 83 with a median age of 52.5 years. Genital tuberculosis can be categorized based on the site of infection and semiology; Upper genital tuberculosis affects the fallopian tubes, endometrium, ovaries, and uterus. Lower genital tuberculosis, on the other hand, affect the cervix, vagina, and vulva [5]. Upper genital tuberculosis can manifest with very diverse clinical presentations and lead to a variety of symptoms including amenorrhea, ascites, chronic abdominal pain, pelvic pain, weight loss, fever, and serious complication such as infertility [6]. Lower genital tuberculosis, especially in the vulva, typically manifest as ulcers on the outer surfaces of the vulva. This study showed that the unpleasant appearance of vulvar tuberculosis in patients varies from ulcerative lesions, lymphedema, or grossly hypertrophic lesions to discharging sinuses with different clinical features such as pain and itch. The incidence of vulva tuberculosis was found to be 68% in postmenopausal women. There is no explanation behind the prevalence of vulvar tuberculosis in this age group. Studies have indicated that atrophic endometrium is an unfavorable environment for the growth of Mycobacterium in women who have gone through menopause [7]. Therefore, tuberculosis is more likely to induce infections in the lower genital area in this specific group of women. Diagnosis of vulvar tuberculosis is difficult. The clinical appearance of vulva tubercular ulcers can be quite variable and lead to potential misdiagnosis as a sexually transmitted disease such as syphilis, chancroid, or carcinoma [8]. Weight loss was the predominant symptom identified among all the patients. Although weight loss is a nonspecific indication of tuberculosis and can also be present in many other diseases. However, due to the high prevalence of this symptom among patients, it can raise suspicion of tuberculosis.

The limitation of this study was the absence of complete textual content for some articles within the databases.

Conclusion

Most patients experience prolonged vulva ulcers. Occasionally, due to misdiagnosis, the patient inadvertently received various antibiotics. The typical lesions in female genital TB are epithelioid cell granulomas which may or may not be accompanied by Langerhans giant cells. Following an accurate diagnosis of genital tuberculosis, the majority of the patients exhibited a favorable response to treatment, resulting in the disappearance of illness symptoms.

Acknowledgments: We thank Gonabad University of Medical Sciences for supporting this study.

Ethical Permissions: None declared by the authors.

Conflicts of Interests: The authors had no conflict of interest.

Authors' Contribution: NematiShahri F (First Author), Introduction Writer (20%); Pouresmaeil O (Second Author), Introduction Writer/Assistant Researcher/Discussion Writer (30%); Sharifi A (Third Author), Discussion Writer/Statistical Analyst (10%); Mardani F (Fourth Author), Assistant Researcher/Discussion Writer (10%); Mardaneh J (Fifth Author), Methodologist/Main Researcher/Discussion Writer (30%)

Funding/Support: This work was financially supported by Gonabad University of Medical Sciences, Gonabad, Iran.

References

1- Muneer A, Macrae B, Krishnamoorthy S, Zumla A. Urogenital tuberculosis-epidemiology, pathogenesis and clinical features. Nat Rev Urol. 2019;16(10):573-98.

2- Hsu CT, Yang LC, Hsu ML, Chen WH, Lin UN. The coexistence of carcinoma and tuberculosis in the uterine cervix: Report of 2 cases. Asia-Ocean J Obstet Gynaecol. 1985;11(3):363-9.

3- Lee JY. Diagnosis and treatment of extrapulmonary tuberculosis. Tuberc Respir Dis. 2015;78(2):47-55.

4- Gatongi DK, Gitau G, Kay V, Ngwenya S, Lafong C, Hasan A. Female genital tuberculosis. Obstet Gynaecol. 2005;7(2):75-9.

5- Chowdhury NN. Overview of tuberculosis of the female genital tract. J Indian Med Assoc. 1996;94(9):345-61.

6- Carton I, Balès D, Bargain A, Lemoine PLP. Vaginal tuberculosis as differential diagnosis of cancer: A case report. J Gynecol Obstet Hum Reprod. 2021;50(6):101873.

7- Güngördük K, Ulker V, Sahbaz A, Ark C, Tekırdag AI. Postmenopausal tuberculosis endometritis. Infect Dis Obstet Gynecol. 2007;2007:27028.

8- Kaur T, Dhawan S, Aggarwal A, Bansal S. Vulval tuberculosis. J Obstet Gynaecol India. 2012;62(4):450-1.

9- Sardana K, Koranne RV, Sharma RC, Mahajan S. Tuberculosis of the vulva masquerading as a sexually transmitted disease. J Dermatol. 2001;28(9):505-7.

10- Manidakis LG, Angelakis E, Sifakis S, Stefanaki P, Kalogeraki A, Manidaki A, et al. Genital tuberculosis can present as disseminated ovarian carcinoma with ascites and raised Ca-125: A case report. Gynecol Obstet Invest. 2001;51(4):277-9.

11- Lamba H, Byrne M, Goldin R, Jenkins C. Tuberculosis of the cervix: Case presentation and a review of the literature. Sex Transm Infect. 2002;78(1):62-3.

12- Lam SK, Chan KS, Chin R. A rare case of vulvar tuberculosis. Hong Kong J Gynaecol Obstet Midwifery. 2007;7(1):56.

13- Akhlaghi F, Farazmand T. A rare case report of tuberculosis of the cervix and vulva in Zeinab Hospital in Mashhad. Razi J Med Sci. 2004;11(40):181-4. [Persian]

14- Krynytska I, Firket C. Genital tuberculosis in postmenopausal patients. J Obstet Gynaecol. 2007;27(4):444-5.

15- Paprikar M, Biswas M, Bhattacharyav S, Sodhi B, Mukhopadhyay I. Tuberculosis of cervix. Med J Armed Forces India. 2008;64(3):297-8.

16- Agrawal S, Madan M, Leekha N, Raghunandan C. A rare case of cervical tuberculosis simulating carcinoma cervix: A case report. Cases J. 2009;2:161.

17- Gupta R, Dey P, Jain V, Gupta N. Cervical tuberculosis detection in Papanicolaou-stained smear: Case report with review of literature. Diagn Cytopathol. 2009;37(8):592-5.

18- Ilmer M, Bergauer F, Friese K, Mylonas I. Genital tuberculosis as the cause of tuboovarian abscess in an immunosuppressed patient. Infect Dis Obstet Gynecol. 2009;2009:745060.

19- Buppasiri P, Temtanakitpaisan T, Somboonporn W. Tuberculosis at vulva and vagina. J Med Assoc Thai. 2010;93(5):613-5.

20- Keshavarzi F, Fakheri T, Nankali A. Vulvar tuberculosis in a virgin girl: A rare case report. Int J Collab Res Intern Med Public Health. 2012;4(5):825-8.

21- Shen HP, Chang WC, Hsieh CH, Yang TC, Hung YC. Vulvar tuberculosis. Taiwan J Obstet Gynecol. 2011;50(1):106-8.

22- Kitisupornpun S, Mahanupab P, Intapibool S. A case report; Tuberculosis of the vulva. Chiang Mai Med J. 2011;50(4):123-8.

23- Jiménez-Gallo D, Navas-García N, Albarrán-Planelles C, Guerrero-Sánchez F. Periorificial cutaneous tuberculosis of the vulva. ACTAS Dermo-Sifiliográficas. 2012;103(10):929-30.

24- Agrawal DR. Primary tuberculosis vulva-A case report. Natl J Integr Res Med. 2013;4(1):142-3.

25- Krishnendu M, Shwetank M, Malay B, Dilip P, Moumita M, Partha PM. Primary vulval tuberculosis presenting as multiple vulval ulcers: A rare case report. UroToday Int J. 2013;6(3):39.

26- Goyal BK, Pradhan S, Jose T, Duggal BS, Sengupta P. Woody vulva: An unusual presentation of vulvar tuberculosis. J Obstet Gynaecol India. 2014; 64(Suppl 1):85-7.

27- Iftikhar N, Kiyani S. A rare case of vulval tuberculosis. Isra Med J. 2015;7(2):111-3.

28- Arya S, Nyati A, Bunkar M, Takhar RP, Mirdha S. Cutaneous lymphangiectasia of the vulva secondary to pulmonary tuberculosis: A case report. Int J Res Dermatol. 2015;1(1):14-16.

29- Oliveira M, Vita-Campos C, Jeunon T. Vulvar tuberculosis cutis orificialis concomitant to pulmonary tuberculosis: A case report. Am J Dermatopathol. 2018;40(12):908-11.

30- Paudel V, Chudal D, Pokhrel DB. Tuberculosis and HIV co-infection; The deadly duos in vulva. Indian J Tuberc. 2018;65(4):277-9.

31- Arora A, Sadath SA. Genital tuberculosis in postmenopausal women with variable clinical presentations: A report of 3 cases. Case Rep Womens Health. 2018;18:e00059.

32- Chishti U, Elorbany S, Akhtar M, Williams J, Heenan S, Barton DP. Genital tuberculosis in a post-menopausal Caucasian woman: A case report. J Obstet Gynaecol. 2019;39(2):284-5.

33- Bragança C, Gonçalves I, Guerreiro L, Janeiro M. Vulvar tuberculosis-A rare manifestation of the disease. Revista Brasileira de Ginecologia e Obstetrícia. 2019;41(9):575-8.

34- Fowler ML, Mahalingaiah S. Case report of pelvic tuberculosis resulting in Asherman's syndrome and infertility. Fertil Res Pract. 2019;5:8.

35- Singh V, Singh G, Sinha RJ, Babu S. Vulvar tuberculosis. BMJ Case Rep. 2020;13(2):e232880.

36- Cheng M, Yuan T, Liu Y. A woman with disseminated tuberculosis experienced preterm delivery, fallopian tube pregnancy, and delivered successfully following in vitro fertilization: A case report. BMC Pregnancy Childbirth. 2021;21:27.